

**SUMMARY:**

- 84 year old
- Venous Leg Ulcer 6 weeks
- Scab week 4 healed week 6

**PATIENT INFORMATION: Miss D, 84 year old female.**

An 84 year old female patient Miss D has a history of recurrent venous ulceration and has impaired mobility due to arthritis in her hips. Miss D had periods of non-compliance to Compression bandaging. Weekly 4 layer compression bandages were applied.

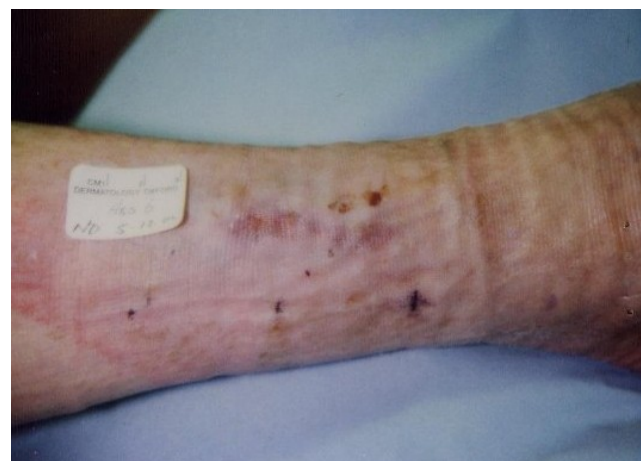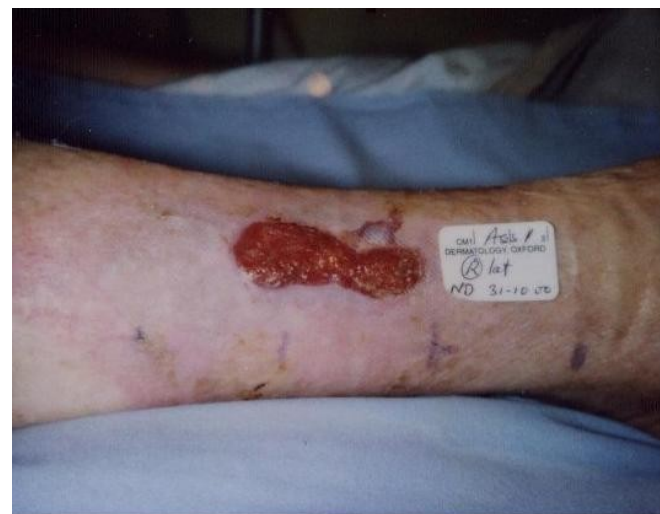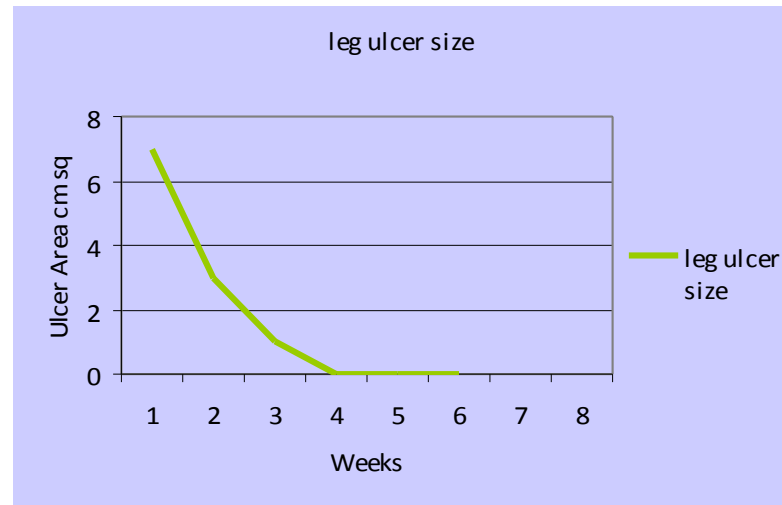
On commencing cycloidal vibration therapy (VIBRO-PULSE™) Miss D had an ulcer on her right lateral gaiter, size 7cmsq.

**Cycloidal Vibration Therapy (VIBRO-PULSE™):** started 3 x a day for 30 minutes per treatment. Miss D self administered the treatment.

**DRESSINGS / BANDAGING:** Miss D continued to receive weekly compression bandaging.

**EXUDATE:** there was a moderate amount of wound exudate

**PAIN:** scale (0 = no pain to 5 = severe) Miss D recorded a score of 2.



*Right leg before and after 6 weeks VIBRO-PULSE therapy*

**WEEK 3 of VIBRO-PULSE™:**

**WOUND:** The leg ulcer was 90% healed to form a scab.

**EXUDATE:** there was no wound exudate.

**PAIN:** scale (0 = no pain to 5 = severe) Miss D recorded a score of 0.5

**WEEK 4 of VIBRO-PULSE™:**

**WOUND:** The leg ulcer had healed and formed a scab.

**WEEK 6 of VIBRO-PULSE™:**

**WOUND:** The scab had resolved and the wound had healed.

**SATISFACTION:** Miss D commented that not only had her pain reduced but she had not experienced any pain at night since starting the treatment and that her mobility had also improved.