

VIBRO-PULSE™ CASE STUDY: Venous leg ulceration.

SUMMARY:

- 76 year old
- Venous Leg Ulcer 6 weeks
- wound healing by week 6.

PATIENT INFORMATION: Mrs H, 76 year old female.

Has a long history of venous ulceration. she last healed after using VIBRO-PULSE™ 13 months ago.

Unfortunately a breakdown had caused superficial ulceration on the left medial gaiter of 11.75cm sq.

On commencing cycloidal vibration therapy (VIBRO-PULSE™) the ulcer which had been present for 6 weeks.

Cycloidal Vibration Therapy (VIBRO-PULSE™): started 2 x a day for 30 minutes per treatment. Mrs H self administered the treatment.

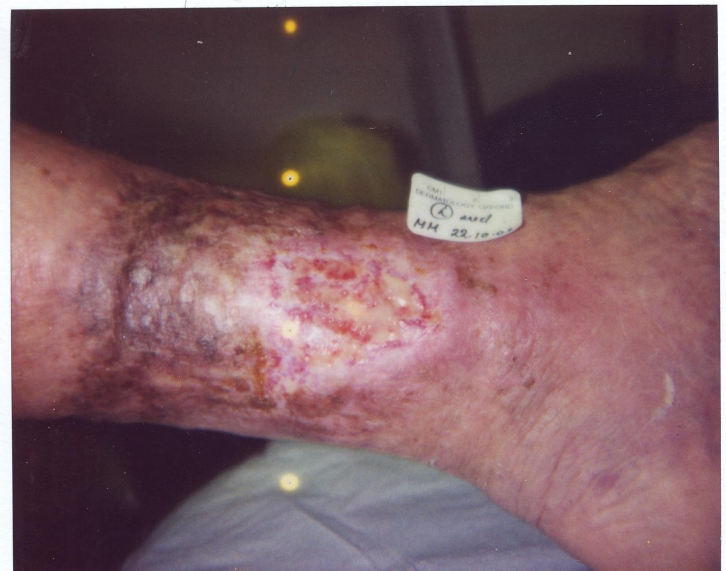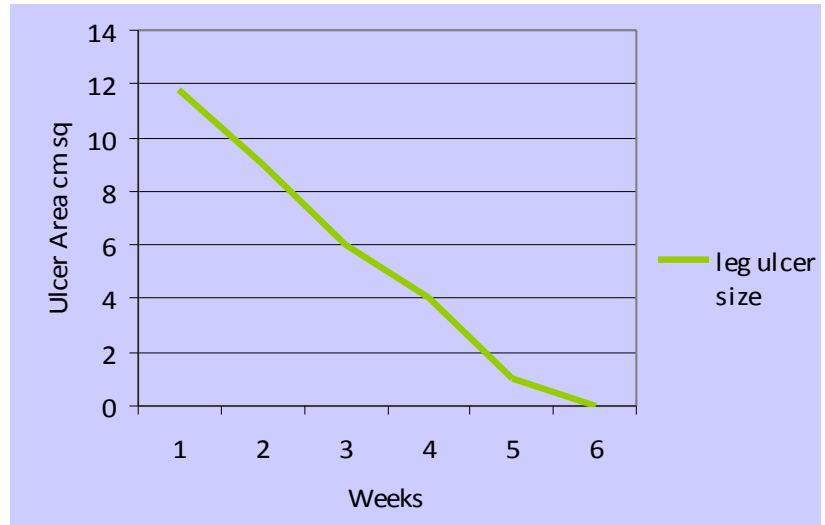
WEEK 5 of VIBRO-PULSE™:

WOUND: The ulcer had reduced in size by 96%.

WEEK 6 of VIBRO-PULSE™:

WOUND: .After 6 weeks the ulcer had healed.

SATISFACTION: Mrs H commented on how she felt proactive in doing something to help her ulcer healing.



Left leg before and after 6 weeks VIBRO-PULSE™ therapy

