

SUMMARY:

- 69 year old
- Venous Leg Ulcer 6 months / stasis eczema
- healed week 14

PATIENT INFORMATION: Mr P, 69 year old male.

A 69 year old male patient Mr P has a history of venous ulceration and stasis eczema. Twice weekly compression bandages had been applied for 6 months

On commencing cycloidal vibration therapy (VIBRO-PULSE™) Mr P had an ulcer on his left medial gaiter, size 8 cm sq.

The stasis eczema had been treated with Trimovate, reduced to Betnovate RD. Hyperkeratotic skin on and around the ulcer proved a problem with occasional breakdown of small open areas of skin.

Cycloidal Vibration Therapy (VIBRO-PULSE™): started 3 x a day for 30 minutes per treatment. Mr P self administered the treatment.

BANDAGING: Mr P continued to receive twice weekly compression bandaging changes.

PAIN: Mr P stated he suffered with ulcer pain.

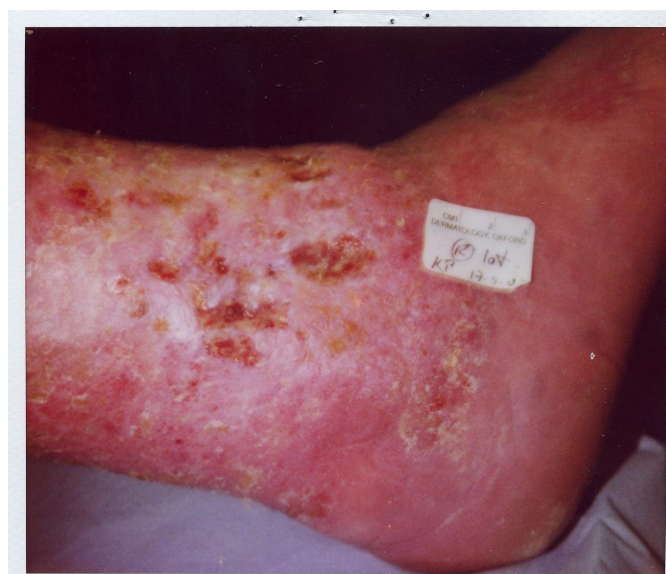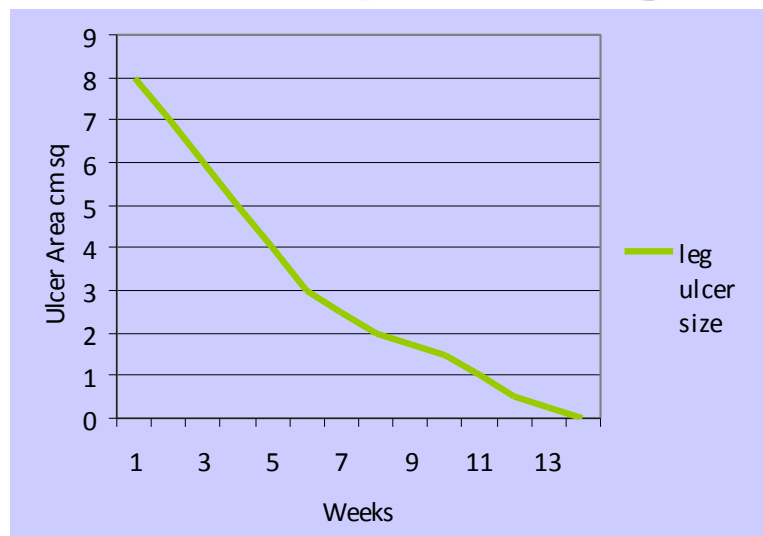
WEEK 9 of VIBRO-PULSE™:

WOUND: The leg ulcer had reduced in size by 78%. (1.75cm sq)

PAIN: Mr P stated his pain had reduced significantly.

WEEK 14 of VIBRO-PULSE™:

WOUND: The leg ulcer had healed but skin remained hyperkeratotic..



Left leg before and after 9 weeks VIBRO-PULSE therapy

