

VIBRO-PULSE™ CASE STUDY: Venous leg ulceration.

SUMMARY:

- 85 year old
- Bilateral Venous Leg Ulcers
Left Leg **12 months**
Right Leg ulcer x 2
medial and lateral **3 years**.
- Week 10 Right medial healed.
- Week 12, 66% reduction in other ulcers.

PATIENT INFORMATION: Mrs B, 85 year old female.

A 85 year old female patient Mrs B has a long history venous ulceration. Weekly compression bandages were applied.

On commencing cycloidal vibration therapy (VIBRO-PULSE™) Mrs B had:

WOUNDS: Left leg ulcer 6cm, duration 12 months. Right leg medial ulcer 22.5cm sq, duration 3 years. Right leg lateral ulcer 43.25cm sq duration 3 years.

Cycloidal Vibration Therapy (VIBRO-PULSE™): started 3 x a day for 30 minutes per treatment. Miss D self administered the treatment.

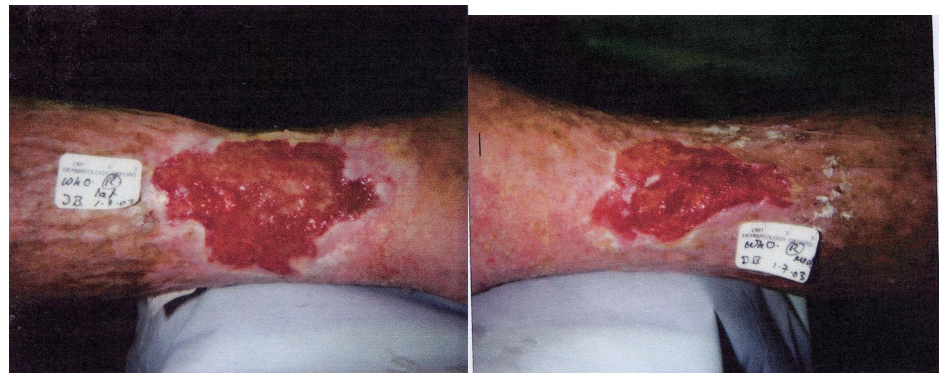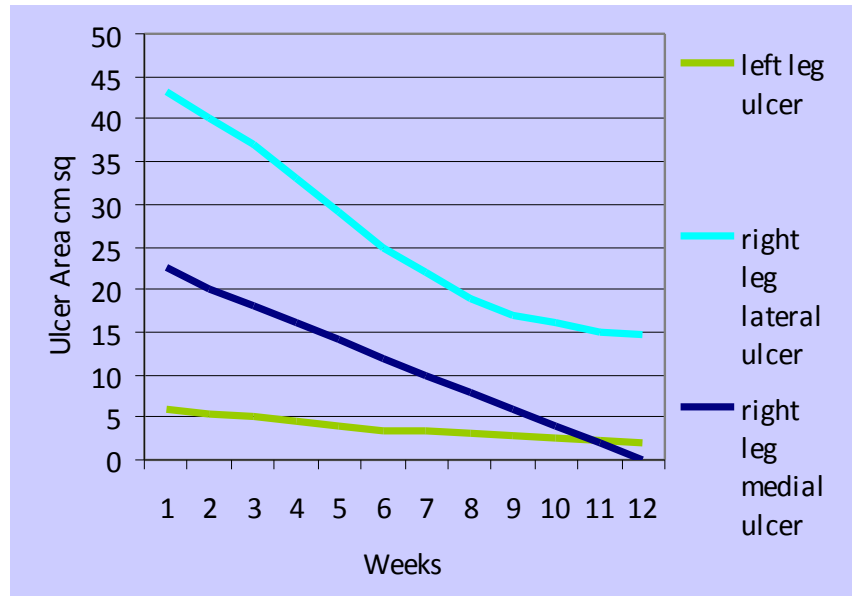
DRESSINGS / BANDAGING: Mrs B continued to receive weekly compression bandaging.

WEEK 10 of VIBRO-PULSE™:

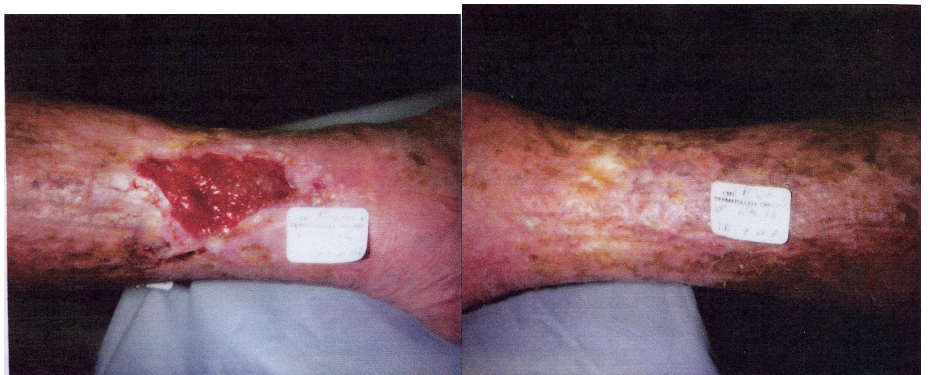WOUNDS: Right leg medial ulcer healed.

WEEK 12 of VIBRO-PULSE™:

WOUNDS: Left leg ulcer 2cmsq 66% area reduction. Right leg lateral ulcer 14.6cmsq 66% area reduction.



Right lateral and medial leg ulcer before



Right lateral and medial leg ulcer after 12 weeks VIBRO-PULSE therapy

SATISFACTION: Mrs B was pleased to finally see her ulcers improve.