

SUMMARY:

- 86 year old
- Venous Leg Ulcer 4 months
- Healed week 5

PATIENT INFORMATION: Mrs R, 86 year old female.

An 86 year old female patient Mrs R has a history of rheumatoid arthritis, DVT and ulceration on the left leg.

On commencing cycloidal vibration therapy (VIBRO-PULSE™) Mrs R had a superficial sloughy ulcer on the left lateral gaiter, with oedema and strophie blanche.

The 7cmsq ulcer had been present for 4 months and Mrs R had been in compression bandaging changed twice a week.

Cycloidal Vibration Therapy (VIBRO-PULSE™): started 3 x a day for 30 minutes per treatment. Mrs R self administered the treatment.

DRESSINGS / BANDAGING: Mrs R continued to receive twice weekly compression bandage changes.

EXUDATE: there was a moderate amount of wound exudate

PAIN: scale (0 = no pain to 5 = severe) Mrs R recorded a score of 2.

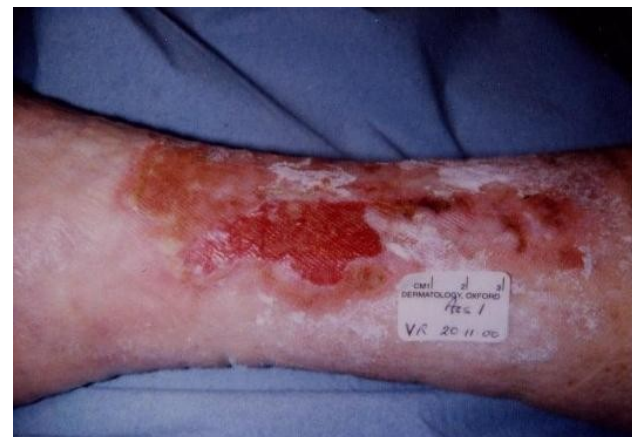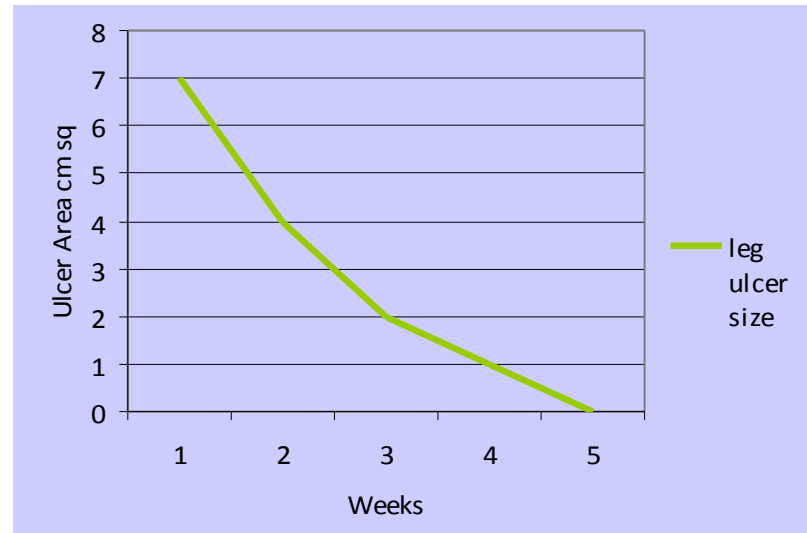
WEEK 3 of VIBRO-PULSE™:

EXUDATE: there was minimal wound exudate.

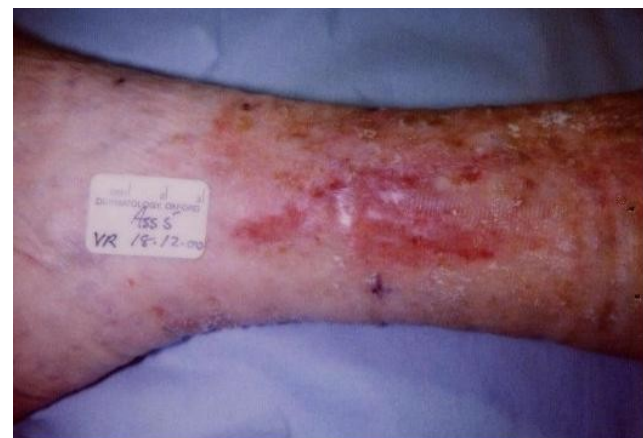PAIN: scale (0 = no pain to 5 = severe) Mrs R recorded a score of 0.

WEEK 5 of VIBRO-PULSE™:

WOUND: The leg ulcer had healed.



Left leg before and after 5 weeks VIBRO-PULSE therapy



SATISFACTION: Mrs R commented on how pleased she was as a result of her ulcer healing.